

Triple Negative Invasive Ductal Carcinoma of Breast with Oral Metastasis: A Case Report

SABARITHA RAMAMOORTHY¹, PRASANTH THANKAPPAN², ISAAC JOSEPH THARMAAHAYAM³,
JESLIN MARY SAMRAJ⁴, EVELYN ANGEL STEPHEN⁵



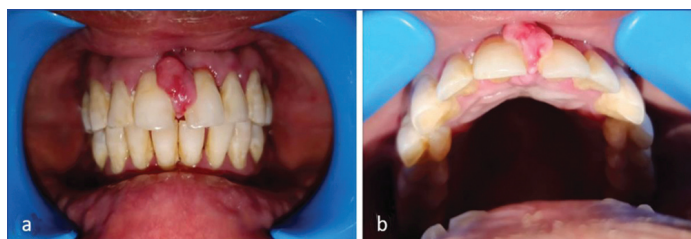ABSTRACT

Metastatic oral malignancies have been reported in the mandible, tongue, and gingiva. Oral metastasis of breast cancer typically presents as a benign oral lesion clinically. However, at histology, it shares several features with metastatic carcinoma, and Immunohistochemistry (IHC) can be useful in the differential diagnosis. The clinical presentation in this case report consisted of swelling in the upper front tooth region in a 35-year-old woman. The lesion was excised under local anaesthesia and underwent histological and immunohistochemical examination to rule out any malignancy. The histological findings, including Pan CK positivity suggesting an epithelial origin and the absence of reactivity to Oestrogen Receptor (ER), Progesterone Receptor (PR), and Human Epidermal Growth Factor Receptor-2 (HER2) indicated metastatic triple negative breast carcinoma. The histological diagnosis of metastatic breast carcinoma can be confirmed by IHC. The current case report illustrates the necessity of including a panel of IHC markers in confirming the diagnosis of metastatic lesions in oral cavity. By utilising such panels, one can expedite the prognosis and prevent delay in diagnosis.

Keywords: Gingiva, Immunohistochemistry, Metastatic breast cancer

CASE REPORT

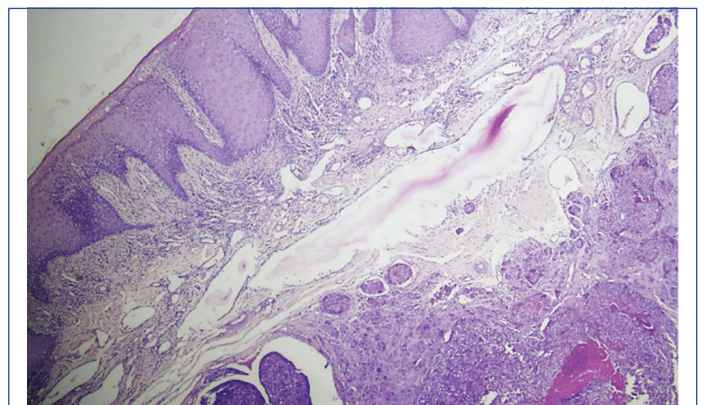
A 35-year-old female with a chief complaint of swelling in the upper front tooth region for past one month, was referred to the dental Outpatient Department (OPD). On intraoral examination, swelling measuring about 1×1 cm was seen on the buccal aspect of 11 and 21, involving the interdental papilla and extending to the palatal aspect which was of size 0.5×0.8 cm [Table/Fig-1]. The patient was asymptomatic and the lesion was neither painful nor bleeding. Her medical history revealed that she had been diagnosed with invasive ductal carcinoma of breast, stage III and underwent mastectomy followed by radiotherapy. She was still under chemotherapy when she presented with gingival swelling eight months after the initial diagnosis of breast carcinoma. Since the gingival lesion was small measuring approximately 1 cm in diameter and clinically resembled pyogenic granuloma, the lesion was excised under local anaesthesia.



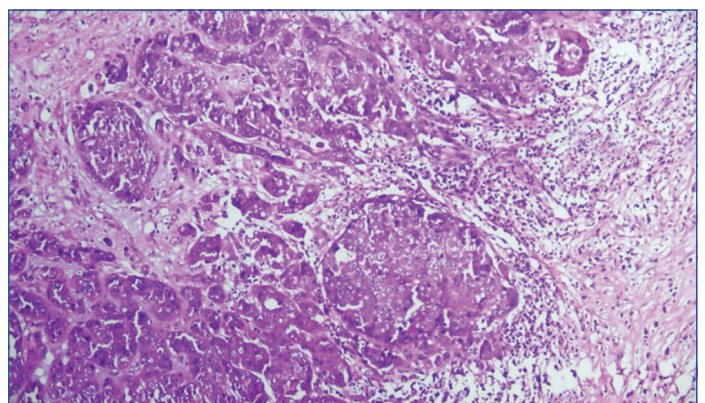
[Table/Fig-1]: Gingival swelling seen on the buccal aspect of 11 and 21, involving the interdental papilla and extending upto the palatal aspect.

Histopathology revealed islands of proliferating dysplastic epithelial cells in the connective tissue stroma which showed cellular and nuclear pleomorphism, increased nuclear cytoplasmic ratio, abnormal mitosis and nuclear hyperchromatism. Some of the dysplastic islands showed central necrosis resembling comedonecrosis. Connective tissue stroma also consisted of bundles of collagen fibers, fibroblast, blood vessels, and chronic inflammatory cell infiltrate consisting of lymphocytes, plasma cell, and macrophages. The lesion was covered by parakeratinised stratified squamous intact epithelium [Table/Fig-2,3]. These findings were consistent with the metastatic carcinoma of breast origin according to the patient's history, histopathological examination of previous biopsy of breast carcinoma report. Therefore, IHC examination was performed to confirm the diagnosis. IHC was done with the markers ER, PR, HER2, Pan CK

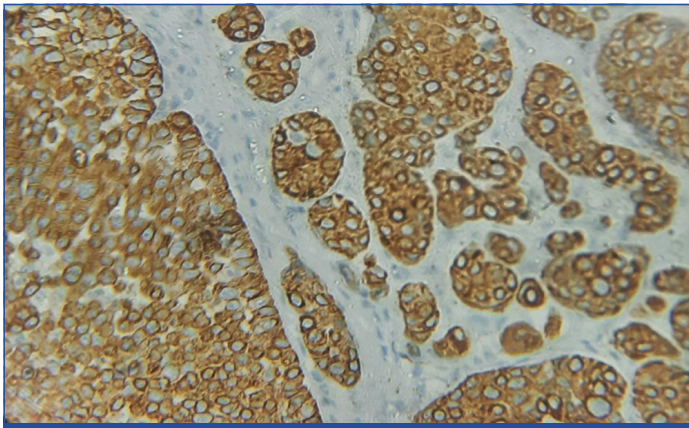
in the gingival biopsy tissue sample. In that, ER, PR, HER2 were all negative indicating triple- negative breast cancer. It grows and spreads faster than most other types of breast cancer. Positive staining for Pan CK indicates that the tumour is of epithelial origin [Table/Fig-4]. These findings were correlated with the previous primary invasive ductal carcinoma of breast which was also negative for ER, PR and HER2, thus confirming the diagnosis of metastatic triple negative invasive ductal carcinoma of breast to gingiva.



[Table/Fig-2]: Haematoxylin and Eosin stained soft tissue section showing islands of proliferating dysplastic epithelial cells and comedonecrosis (40x) (gingival biopsy).



[Table/Fig-3]: Haematoxylin and Eosin stained soft tissue section showing infiltrating ductal neoplasm arranged in cords, trabeculae, sheets and invasive nests (100x) (breast biopsy).



[Table/Fig-4]: Positive immunohistochemical staining for Pan CK indicating that the tumour is of epithelial origin (400x) (gingival biopsy).

Radiotherapy of 3000cGy was administered initially, which was divided in to 10 fractions and then she was started on chemotherapy with Paclitaxel. When she developed gingival growth, she was advised to undergo Positron Emission Tomography (PET) scan which showed distant metastasis to various parts of the body for which she was given Eribulin of 2 mg in a weekly interval. However, she passed away five months after the diagnosis of gingival metastasis.

DISCUSSION

Metastasis is more common in the jaw bone than in soft tissue, as shown by Hirshberg A et al., who reviewed 111 cases of breast carcinoma out of 673 cases, in which 91 cases reported jawbone metastasis and 20 cases showed soft tissue metastasis. It usually involves the mandible rather than the maxilla. In the case of soft tissue involvement, the gingiva is the most common site of metastasis [1]. To the best of our knowledge in English literature, so far only three cases have been reported on Triple Negative Breast Cancer (TNBC) in women with metastasis to maxilla, maxillary mucosa and buccal mucosa [Table/Fig-5] [2-4]. Among the three cases, two were involving soft tissue covering the maxilla and one involving the maxillary bone and soft tissue. All the three cases showed ulceroproliferative growth clinically. The present case showed growth in the maxillary gingiva without any ulceration.

Case no.	Author name and year	Age/Gender (years)	Type of breast carcinoma	Site of metastasis	Involvement of bone/soft tissue	Survival
1.	Nikolova D et al., [2] Germany (2021)	44/F	Triple-negative carcinoma	Maxillary mucosa	Mucobuccal, mucolabial fold and palate (Soft tissue)	<3 years
2.	Wuraola FO et al., [3] Nigeria (2021)	42/F	Infiltrating ductal carcinoma Not Otherwise Specified (NOS) (triple negative)	Maxilla and palate	Right maxillary central incisor region to the right maxillary tuberosity (Bone and soft tissue)	<1 year
3.	Jain S et al., [4] New Delhi, India (2013)	30/F	Infiltrating ductal carcinoma (triple negative)	Buccal mucosa	Soft tissue	Not mentioned
4.	Present case Tamil Nadu, India (2023)	35/F	Invasive ductal carcinoma (triple negative)	Maxillary gingiva	Soft tissue	<1 year

[Table/Fig-5]: Previously reported cases of breast carcinoma (Triple negative) with metastasis to the oral cavity (last 10 years).

TNBC is defined immunohistochemically as breast cancer that does not overexpress HER2 and is ER, PR negative [5]. It includes a morphologically heterogenous group of carcinomas many of which are rarely encountered. These include a subgroup of Invasive Ductal Carcinomas (IDC) Not Otherwise Specified (NOS), medullary carcinomas, apocrine carcinomas, adenoid cystic carcinomas, and metaplastic carcinomas. Here, the reported case is TNBC of the IDC NOS subtype, which is probably the most common morphologic variant noted. They commonly occur in younger women, below 40 years of age, in women of African American ancestry and women of low socioeconomic status [6].

Important biomarkers linked to breast cancer include the ER, PR, HER2, Ki-67 index, and p53 status. In the absence of a prior history of breast cancer, it may be challenging to identify metastatic carcinoma of the breast. To help with this process, numerous

immunophenotypic markers have been developed. Hormone receptors, such as Androgen Receptors (ARs) and gross cystic disease fluid protein 15, are indicators of mammary origin (GCDFP-15). Additionally, ER, PR, HER-2/neu, mammaglobin, and CKs (7 and 20) are included in the diagnostic panel [7].

Coexpression of CK7, GATA3, and ER is highly suggestive of metastatic breast cancer in the context of IHC stains, which are frequently used for the work-up of carcinoma of unknown primary. ER can be used as both a diagnostic marker and a treatment target, in contrast to HER2, which is typically only used as a therapeutic target. Breast and gynaecological carcinomas are the two distinct female tumours for which ER is a specific marker, and luminal Invasive Breast Carcinomas (IBCs) are highly sensitive to ER. TRPS1 and GATA3 are used in conjunction because they can support one another. GATA3 can detect IBC with apocrine features, a unique type of TNBC that is negative for TRPS1, while TRPS1 detects almost all GATA3 negative and triple-negative IBC-NSTs (IDC) [8].

Even though they are characterised immunohistochemically, histologic features also suggest a triple-negative immunophenotype. TNBCs are distinguished by a high histologic grade, central necrotic zones, and pushing borders. Triple-negative tumours frequently exhibit cellular fibrous proliferation, whereas non-TNBCs have fibrosis with a higher degree of hyalinisation. TNBCs frequently have variable-sized blood vessels, including thick-walled vessels [5].

Patients with TNBC tend to experience a relapse more quickly and have a higher likelihood of developing central nervous system and visceral metastases [5]. However, the present case has reported early metastasis to gingiva within eight months. This is probably due to the circulating tumour cells that may become entrapped in the rich capillary network of chronically inflamed attached gingiva and the new proliferating capillaries have a fragmented basement membrane and are leaky, making them more permeable to tumour cells than mature vessels [2] and further the periodontal inflammation promotes metastasis of breast cancer by recruiting myeloid-derived suppressor cells by pyroptosis- induced IL-1β generation and downstream CCL2, CCL5, CXCL5 signalling [9]. Women with triple-negative breast cancer who have been disease-free for eight years appear to be less likely to die of breast cancer, despite having

a high risk of early recurrence [10]. In the present reported case the patient had an early recurrence within a year and she passed away five months after the diagnosis of gingival metastasis. This is in accordance with the metastatic breast carcinoma case reported by Nikolova D et al., in which she passed away five months after the maxillofacial procedure. The cause of death was deemed to be the widespread metastatic triple negative disease [2].

TNBC has the worst prognosis of all the subtypes of breast cancer. It has a distinct recurrence pattern, with the highest risk of recurrence and the majority of deaths occurring in the first three and five years, respectively, after initial treatment [11]. TNBC patients cannot be treated with endocrine therapy or HER2-specific therapies and therefore requires special treatment approaches [12]. But this patient had already severe distant metastasis and was put under only palliative chemotherapy as she had worst prognosis. Although

gingival involvement is not common in metastatic triple-negative breast cancer, it must be considered to prevent delay in diagnosis and improve patient outcomes. In the reported case, tumour mass was first evident in the oral cavity which helped to further rule out the other distant metastases.

CONCLUSION(S)

The TNBC rarely metastasises to the oral cavity, especially the gingiva. In this case, oral lesions were the first to manifest clinically. IHC was indicated to confirm the diagnosis because the primary tumour also showed similar triple negative response to ER, PR and HER2. Potential diagnostic errors can be avoided by using immunohistochemical analyses, specifically for excluding the clinically apparent benign oral lesions.

REFERENCES

- [1] Hirshberg A, Shnaiderman-Shapiro A, Kaplan I, Berger R. Metastatic tumours to the oral cavity-pathogenesis and analysis of 673 cases. *Oral Oncol.* 2008;44(8):743-52.
- [2] Nikolova D, Papacharalambous S, Iacovou E, Marcou Y, Katodritis N, Nikolova D. A rare case report of metastatic breast carcinoma in the Oral mucosa and literature review. *Hellenic archives of Oral & Maxillofacial Surgery.* 2021;1:19-26.
- [3] Wuraola FO, Famurewa BA, Olasehinde O, Odujoko OO, Adesina OM, Aregbesola SB. From the breast to the upper jaw: A rare case of metastatic breast cancer. *South Sudan Medical Journal.* 2021;14:60-63.
- [4] Jain S, Kadian M, Khandelwal R, Agarwal U, Bhowmik KT. Buccal metastasis in a case of carcinoma breast: A rare case report with review of literature. *Int J Surg Case Rep.* 2013;4(4):406-08.
- [5] Schmadeka R, Harmon BE, Singh M. Triple-negative breast carcinoma: Current and emerging concepts. *Am J Clin Pathol.* 2014;141(4):462-77.
- [6] Bose S. Triple-negative breast carcinoma: Morphologic and molecular subtypes. *Adv Anat Pathol.* 2015;22(5):306-13.
- [7] Zaha DC. Significance of immunohistochemistry in breast cancer. *World J Clin Oncol.* 2014;5(3):382-92.
- [8] Ding Q, Huo L, Peng Y, Yoon EC, Li Z, Sahin AA. Immunohistochemical markers for distinguishing metastatic breast carcinoma from other common malignancies: Update and revisit. *Semin Diagn Pathol.* 2022;39(5):313-21. Doi: 10.1053/j.semdp.2022.04.002.
- [9] Cheng R, Billet S, Liu C, Haldar S, Choudhury D, Tripathi M, et al. Periodontal inflammation recruits distant metastatic breast cancer cells by increasing myeloid-derived suppressor cells. *Oncogene.* 2020;39:1543-56.
- [10] Dent R, Trudeau M, Pritchard KI, Hanna WM, Kahn HK, Sawka CA, et al. Triple-negative breast cancer: Clinical features and patterns of recurrence. *Clin Cancer Res.* 2007;13(15 Pt 1):4429-34.
- [11] Ovcariček T, Frković S, Matos E, Mozić B, Borstnar S. Triple negative breast cancer-prognostic factors and survival. *Radiol Oncol.* 2011;45(1):46-52.
- [12] Al-Mahmood S, Sapiezynski J, Garbuzenko OB, Minko T. Metastatic and triple-negative breast cancer: Challenges and treatment options. *Drug Deliv Transl Res.* 2018;8(5):1483-507. Doi: 10.1007/s13346-018-0551-3.

PARTICULARS OF CONTRIBUTORS:

1. Postgraduate, Department of Oral Pathology, Sree Mookambika Institute of Dental Sciences, Kanyakumari, Tamil Nadu, India.
2. Professor, Department of Oral Pathology, Sree Mookambika Institute of Dental Sciences, Kanyakumari, Tamil Nadu, India.
3. Professor and Head, Department of Oral Pathology, Sree Mookambika Institute of Dental Sciences, Kanyakumari, Tamil Nadu, India.
4. Assistant Professor, Department of Oral Pathology, Sree Mookambika Institute of Dental Sciences, Kanyakumari, Tamil Nadu, India.
5. Associate Professor, Department of General Pathology, Sree Mookambika Institute of Dental Sciences, Kanyakumari, Tamil Nadu, India.

NAME, ADDRESS, E-MAIL ID OF THE CORRESPONDING AUTHOR:

Prasanth Thankappan,
Professor, Department of Oral Pathology, Sree Mookambika Institute of Dental Sciences,
Kulasekharam, Kanyakumari, Tamil Nadu, India.
E-mail: prasanthi2020@gmail.com

PLAGIARISM CHECKING METHODS: (Lain H et al.)

- Plagiarism X-checker: Dec 05, 2022
- Manual Googling: Feb 16, 2023
- iThenticate Software: Mar 03, 2023 (20%)

ETYMOLOGY: Author Origin

AUTHOR DECLARATION:

- Financial or Other Competing Interests: None
- Was informed consent obtained from the subjects involved in the study? Yes
- For any images presented appropriate consent has been obtained from the subjects. Yes

Date of Submission: **Dec 01, 2022**

Date of Peer Review: **Jan 18, 2023**

Date of Acceptance: **Mar 18, 2023**

Date of Publishing: **May 01, 2023**